

Technical Note

The Modified Beachchair Position for Arthroscopic Shoulder Surgery: The La Jolla Beachchair

Heinz R. Hoenecke, M.D., Jan Fronek, M.D., and Mary Hardwick, R.N., M.S.N.

Abstract: Arthroscopic surgery of the shoulder is usually performed in the lateral decubitus or beachchair position. The modified beachchair position described here allows arthroscopic procedures to be performed as in the lateral position yet maintains a semiupright orientation and permits conversion to open procedures as in the beachchair position. The results of this technique are reported for 50 consecutive patients with a variety of diagnoses. This modified beachchair position was found to be quickly and easily accomplished with a minimum of special equipment. **Key Words:** Arthroscopy—Shoulder—Beachchair—Lateral decubitus.

Arthroscopic surgery of the shoulder is typically performed in the lateral decubitus or the beachchair position. Both approaches offer distinct advantages and potential problems. The beachchair position presents the anatomy in an upright position, minimizing spatial disorientation and offering easy conversion to an open procedure when necessary. This position is also comfortable for the patient when regional anesthesia is used.¹ The potential disadvantages of the beachchair position include the possible need of an assistant or relatively expensive special device to position the arm and provide traction for exposure of the subacromial or intra-articular spaces. Arthroscopic access for axillary pouch and posterior recess could be more difficult than using a lateral approach.²

The lateral decubitus position is popular for arthroscopic surgery because of its stable positioning of the patient with static traction applied in the desired position of abduction and flexion of the arm. Arthroscopic exposure for most parts of the shoulder, espe-

cially anterior, inferior, and posterior capsule, is good. Conversion of the lateral position to an open approach could be more difficult than for the beachchair position, especially for an anterior approach.

The modified beachchair approach offers the best elements of the two current positions. This modified approach was designed to allow for the use of traction such as in the lateral position, yet allow the surgeon to orient the shoulder in the more familiar upright posture and to allow for easy conversion to an open procedure if necessary.

DESCRIPTION

The patient is placed on a standard operating room table. Anesthesia is administered and a triangular foam pillow with beveled ends to fit behind the scapula is used to position the patient in a 45° lateral position (Fig 1). The table is flexed at the hips with the back of the table elevated approximately 30° (Fig 2). The foot of the bed is lowered slightly. The overhead traction bar that is used for the lateral position is used to apply 10 pounds of longitudinal traction with the arm flexed and abducted 30° (Fig 3). If desired, more abduction can be achieved for an instability repair by putting the traction apparatus on the same side as the surgeon at the foot of the bed, although this is not

*From Scripps Clinic, La Jolla, California, U.S.A.
Address correspondence and reprint requests to Heinz R. Hoenecke, M.D., Scripps Clinic, 10666 North Torrey Pines Road, La Jolla, CA 92037, U.S.A. E-mail: bhoeneck@san.rr.com
© 2004 by the Arthroscopy Association of North America
0749-8063/04/2006-3818\$30.00/0
doi:10.1016/j.arthro.2004.04.017*

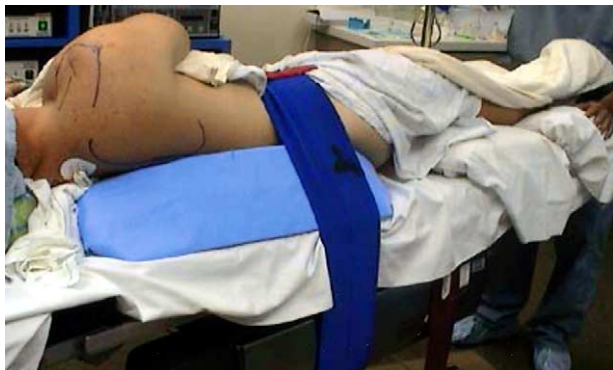

FIGURE 1. Under general anesthesia, the patient is rolled 45° to the nonoperative side with a customized foam pillow. The pillow is designed and positioned to align with the medial border of the scapula.

usually necessary. A foam pillow is used to position the head in neutral position with respect to the body. No axillary pillow is used for the position.

CLINICAL EXPERIENCE

We have reviewed the last 50 procedures performed in this position. The procedures were performed on the right side in 27 patients and on the left in 23 patients. A wide spectrum of problems was noted in this patient population, including subacromial impingement, rotator cuff tears, subscapularis muscle tears, instability, glenoid labrum tears, calcific tendonitis, periprosthetic adhesions, biceps tendonitis, and acromioclavicular joint arthritis. Fifty-five procedures were performed in 50 patients. The procedures included 16 subacromial decompressions/debridements, 5 acromioclavicular joint resections, 21 rotator cuff repairs, 2 slap repairs, 5 anterior instability repairs, 2 subscapularis repairs, 3 capsular releases and debridements, and a single arthroscopy of a hemiarthroplasty.

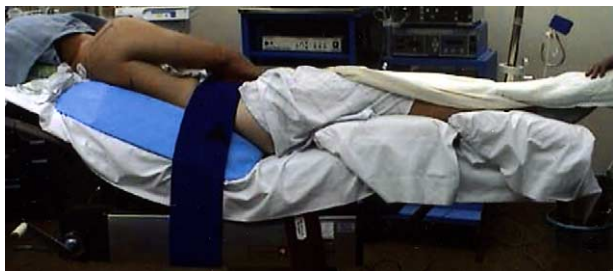

FIGURE 2. The patient is secured with large Velcro straps around the patient, pillow, and table. The table is flexed slightly at the hips and the back of the table is elevated approximately 30°.

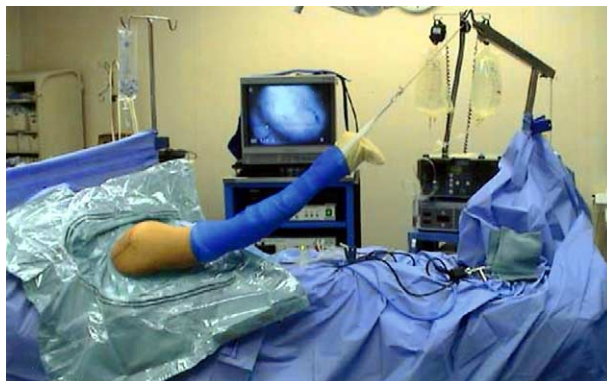

FIGURE 3. Ten pounds of skin traction is applied. The foot of the bed can be lowered slightly to increase distance to the traction apparatus.

Three procedures were converted to an open repair with excellent visualization and access to the surgical site.

Potential complications related to the modified beachchair position or the lateral decubitus position such as neuropraxia, visualization problems, infections, or anesthesia access problems were not encountered. Anesthesia was with a laryngeal mask airway or intubation. On one occasion, the anesthesiologist chose to convert the laryngeal mask airway to intubation and found it easy to do so in this position.

We have noted that this modified beachchair position is efficient for the capture of outflow fluid into the arthroscopic drape pouch. Similar to the lateral decubitus position, gas bubbles from electrocautery or radiofrequency devices tend to flow out the lateral cannula rather than accumulate in the subacromial space when performing arthroscopic rotator cuff surgery. The subjective impression of the technique indicated access to surgical sites was good for arthroscopic or open procedures because the shoulder is positioned at or over the lateral edge of the table (Fig 4).

DISCUSSION

Arthroscopic techniques in the modified beachchair position are very similar to the lateral decubitus position. However, arthroscopic access anteriorly is made while standing anterolaterally or superiorly with respect to the shoulder rather than an across-table anterior approach. Open procedures are very similar to the beachchair position. The modified beachchair position is particularly useful for surgeons learning arthroscopic rotator cuff repair because it allows familiar positioning of the patient with respect to anatomic

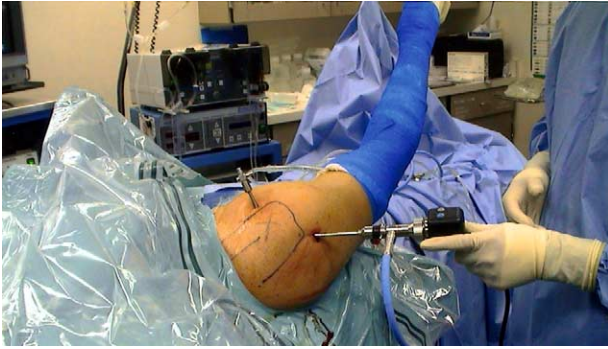


FIGURE 4. The 45° inclination projects the shoulder over the edge of the table and in close proximity to the surgeon, making access to the shoulder easy and allowing for efficient fluid collection.

structures yet allows the use of traction and easy conversion to open repair. Open repair of the rotator cuff after arthroscopy can be completed with the patient in traction or, if desired, the traction can be removed and the bed rolled slightly toward the surgeon, if necessary, to complete procedures through an anterior approach.

Previous literature regarding arthroscopy in the beachchair position have noted potential fogging of the arthroscope lens when an open camera lens system is used as a result of the flow of irrigation down the scope when the camera is held in the “uphill” position from a posterior approach.¹ A sealed camera system was used in this series; therefore, this potential complication was not encountered.

Neurologic complications, which have been reported for the lateral decubitus position, have included compression of the dorsal digital nerve of the thumb, peroneal nerve, and traction-induced trauma to the brachial plexus.^{3,4} These complications were not encountered in this series; however, care was taken to avoid excessive traction or hyperabduction of the arm. The extremities were carefully padded and the head was positioned in a neutral position with respect to the body using a foam headrest.

The potential advantages of the modified beachchair position include the following:

- Easy, rapid positioning of the patient,
- Inexpensive,
- Easy conversion to open surgery,
- Comfortable for the patient and surgeon, and
- Semiupright position minimizes spatial disorientation.

The potential disadvantages include:

- Similar to the standard beachchair position, the modified beachchair does not allow access to the shoulder while standing on the opposite side of the table.
- The modified beachchair position has not yet been demonstrated to be useful when converting from operative arthroscopy to an open anterior instability repair.

In summary, the modified beachchair position is quickly and easily accomplished with a minimum of specialized equipment. The modified beachchair position offers an optional position for the surgeon who wants to enjoy most of the advantages of the lateral decubitus position for arthroscopic procedures yet retain the familiar semiupright orientation and flexibility of the beachchair position.

REFERENCES

1. Skyhar MJ, Altchek DW, Warren RF, Wickiewicz TL, O'Brien SJ. Shoulder arthroscopy with the patient in the beach-chair position. *Arthroscopy* 1988;4:256-259.
2. Cole B. Beach chair position set up. Paper presented at the 19th Annual Meeting of San Diego Shoulder Arthroscopy, San Diego, CA, June 2002.
3. Andrews JR, Carsons WG. Shoulder joint arthroscopy. *Orthopedics* 1983;6:1157-1162.
4. Paulos L. Arthroscopic shoulder decompression technique and preliminary results. Paper presented at the meeting of Arthroscopy Association of North America, Los Angeles, CA, April 1985.